

# Bilaminar techniques for the treatment of recession-type defects. A comparative clinical study

G. Zucchelli<sup>1</sup>, C. Amore<sup>1</sup>,  
N. M. Sforza<sup>1</sup>, L. Montebugnoli<sup>2</sup>  
and M. De Sanctis<sup>1</sup>

Departments of <sup>1</sup>Periodontology, <sup>2</sup>Dental  
Emergency, Bologna University, Bologna,  
Italy

Zucchelli G, Amore C, Sforza NM, Montebugnoli L, De Sanctis M: Bilaminar techniques for the treatment of recession-type defects. A comparative clinical study. *J Clin Periodontol* 2003; 30: 862–870. © Blackwell Munksgaard, 2003.

## Abstract

**Objectives:** Complete root coverage is the primary objective to be accomplished when treating gingival recessions in patients with aesthetic demands. Furthermore, in order to satisfy patient demands fully, root coverage should be accomplished by soft tissue, the thickness and colour of which should not be distinguishable from those of adjacent soft tissue. The aim of the present split-mouth study was to compare the treatment outcome of two surgical approaches of the bilaminar procedure in terms of (i) root coverage and (ii) aesthetic appearance of the surgically treated sites.

**Material and Methods:** Fifteen young systemically and periodontally healthy subjects with two recession-type defects of similar depth affecting contralateral teeth in the aesthetic zone of the maxilla were enrolled in the study. All recessions fall into Miller class I or II. Randomization for test and control treatment was performed by coin toss immediately prior to surgery. All defects were treated with a bilaminar surgical technique: differences between test and control sites resided in the size, thickness and positioning of the connective tissue graft. The clinical re-evaluation was made 1 year after surgery.

**Results:** The two bilaminar techniques resulted in a high percentage of root coverage (97.3% in the test and 94.7% in the control group) and complete root coverage (gingival margin at the cemento-enamel junction (CEJ)) (86.7% in the test and 80% in the control teeth), with no statistically significant difference between them.

Conversely, better aesthetic outcome and post-operative course were indicated by the patients for test compared to control sites.

**Conclusions:** The proposed modification of the bilaminar technique improved the aesthetic outcome. The reduced size and minimal thickness of connective tissue graft, together with its positioning apical to the CEJ, facilitated graft coverage by means of the coronally advanced flap.

Key words: gingival recession; root coverage; pedicle flap; connective tissue graft; aesthetics

Accepted for publication 16 December 2002

Gingival recession can be defined as a shift of the gingival margin to a position apical to the cemento-enamel junction (CEJ) with oral exposure of the root surface (Wennstrom 1994). The consequence of this is a clinical crown lengthening. The presence of gingival recessions at the anterior teeth may represent an aesthetic problem for the

patient who complains about the excessive length of some of his/her teeth. This disharmony may be apparent in the patient's smile or even at a functional level (phonics, chewing). More seldom, root exposure, due to gingival recession, may cause dentine hypersensitivity and consequently patient discomfort and/or inadequate oral hygiene. The irregular

outline of the gingival margin, even in the absence of tooth hypersensitivity, may render plaque control more difficult for the patient, even more so when gingival recession is triangular shaped with acute angles (the so-called "Stillman cleft").

The international literature has thoroughly documented that gingival reces-

sion can be successfully treated using several surgical procedures (Wennstrom 1994), irrespective of the utilized technique, provided the biologic conditions for accomplishing root coverage are satisfied: no loss of interdental soft and hard tissues height (Miller 1985).

The selection of one surgical technique over another depends on several factors, some of which are related to the defect (the size of the recession defect, the presence or absence of keratinized tissue adjacent to the defect, the width and height of the interdental soft tissue, the depth of the vestibulum or the presence of frenuli) while others are related to the patient (Zucchelli & De Sanctis 2000). Furthermore, the clinician must consider data from the literature in order to select the most predictable surgical approach among those feasible in a given clinical situation.

In patients with aesthetic requests if there is adequate keratinized tissue apical or lateral to the recession defect, pedicle flap surgical techniques (coronally advanced or laterally moved flaps) are recommended (Grupe & Warren 1956, Guinard & Caffesse 1978, Tenenbaum et al. 1980, Caffesse et al. 1984, Allen & Miller 1989, Wennstrom & Zucchelli 1996). In these surgical approaches, the soft tissue utilized to cover root exposure is similar to that originally present at the buccal aspect of the tooth with the recession defect, and thus the aesthetic result is satisfactory. Conversely, when the keratinized tissue lateral or apical to the gingival defect is not adequate, free graft procedures have to be performed (Sullivan & Atkins 1968, Mlinek et al. 1973, Matter 1980, Holbrook & Ochslein 1983, Miller 1985, Borghetti & Gardella 1990, Tormie et al. 1991). The use of a free gingival graft to treat recession defects in patients with aesthetic requests is not recommended because of the poor aesthetic outcome and the low root coverage predictability (Wennstrom 1994). The use of a pedicle flap to cover the graft (bilaminar technique) improves the root coverage predictability (as it provides the graft with an additional blood supply) and the aesthetic result because it hides the white-scar colour of the graft and masks the irregular outline of the mucogingival junction that frequently results after a free graft procedure (Langer & Langer 1985, Raetzke 1985, Nelson 1987, Harris 1992, Allen 1994, Bouchard

et al. 1994, Bruno 1994, Wennstrom & Zucchelli 1996).

The recent literature indicates the bilaminar techniques (i.e. partially disepithelized or connective tissue graft covered by a pedicle flap) as highly predictable root coverage surgical procedures (Wennstrom 1994), even if the reported percentage of complete root coverage with the bilaminar procedures ranges from 42% (Raetzke 1985) to 89% (Harris 1992).

During the last two decades, clinicians have introduced several modifications to the original bilaminar procedure described by Raetzke (1985), resulting in more predictable outcomes, in terms of root coverage, and greater aesthetic satisfaction for the patients. These modifications related both the type of graft (partially or completely disepithelized) harvested from the palate and the design (envelope-type or with vertical-releasing incision) of the covering flap.

Some authors used an envelope (Raetzke 1985, Allen 1994) or repositioned flap (Langer & Langer 1985) to cover the epithelial-connective tissue graft partially. Others utilized coronally advanced flaps with (Nelson 1987, Wennstrom & Zucchelli 1996) or without (Bruno 1994) vertical-releasing incisions, or laterally moved papillae flaps (Harris 1992) to cover connective tissue grafts. In all the mentioned surgical approaches, the size of the graft exceeded that of the bone dehiscence and it was positioned (and sutured) at the level of the CEJ.

Although root coverage became more predictable, the aesthetic appearance of the surgically treated area was often in contrast with that of adjacent soft tissues. This was due to a number of reasons:

- (a) the chromatic difference between the uncovered epithelized portion of the graft and the adjacent soft tissues (Langer & Langer 1985, Raetzke 1985, Allen 1994);
- (b) the dischromy associated with the partial exposure of connective tissue graft due to a dehiscence of the covering flap (Nelson 1987, Bruno 1994, Wennstrom & Zucchelli 1996); and
- (c) the difference in thickness between the grafted area and adjacent soft tissues.

The aim of the present study was to compare root coverage and aesthetic results of a modified surgical approach for the bilaminar procedure with those

achieved with a more traditional bilaminar technique.

## Material and Methods

### Subject and site selection

The subject population consisted of 15 young (age range 18–35 years) patients with aesthetic problems due to the exposure of recession-type defects when smiling. The participants were selected on a consecutive basis among patients consulting the Department of Periodontology, University of Bologna. A screening examination revealed that all subjects showed a normal medical history and none had loss of periodontal support at tooth surfaces other than those showing recession defects.

Each subject enrolled in the study presented two recession-type defects, of similar depth (the difference in recession depth should be  $\leq 2$  mm), affecting homologous contralateral teeth in the upper jaw. Only teeth from #15 to #25 were included in the study. All the recession defects fall into class I or II according to the definitions given by Miller (1985), since no loss of interdental soft and hard tissue height was present. The experimental procedure was performed using the split-mouth design. Randomization for test and control treatment was performed by coin toss immediately prior to surgery. All defects were treated with a bilaminar surgical technique (connective tissue graft covered by a coronally advanced flap): differences between test and control surgical approaches resided in the size, thickness and positioning of the connective tissue graft.

Following the screening examination, all subjects received a session of prophylaxis, including instruction in proper oral hygiene measures, scaling and professional tooth cleaning with the use of a rubber cup and a low abrasive polishing paste. A coronally directed roll technique was prescribed for teeth with recession-type defects in order to minimize the toothbrushing trauma to the gingival margin. Surgical treatment of the recession defects was not scheduled until the patient could demonstrate an adequate standard of supragingival plaque control.

### Clinical characterization of patients and selected sites

Full mouth and local plaque scores (FMPS) were recorded as the percen-

tage of total surfaces (four aspects per tooth) that revealed the presence of plaque (O'Leary et al. 1972). Bleeding on probing was assessed dichotomously at a force of 0.3N with a manual pressure-sensitive probe.\* Full mouth (FMBS) and local bleeding score were recorded as the percentage of total surfaces (four aspects per tooth) that revealed the presence of bleeding upon probing.

The following clinical measurements were taken at the facial aspect to the experimental teeth 1 week before the surgery and at 1-year follow-up:

- gingival recession depth (REC depth), measured from the CEJ to the most apical extension of the gingival margin;
- gingival recession width (REC width), measured at the level of the CEJ;
- probing pocket depth (PPD), measured from the gingival margin to the bottom of the gingival sulcus;
- clinical attachment level (CAL), measured from the CEJ to the bottom of the gingival sulcus;
- gingival height (GH), measured from the gingival margin to the mucogingival line.

A single investigator performed the clinical measurements at baseline and after 1 year. He was unaware of the treatment assignment. All measurements were performed by means of a manual probe and were rounded up to the nearest millimetre.

A questionnaire was given to each patient before surgery. It was divided into three parts to be completed by the patient in different time periods:

- the first part, concerning the patient's major problem associated with the presence of recession (excessive tooth length, contrast in colour or lack of gingiva), was completed before surgery;
- the second part, regarding the post-operative course, was completed at the time of suture removal; and
- the third part, concerning the final aesthetic outcome, was completed by the patient at the 1-year follow-up visit.

\*PCP-UNC 15 probe tip, Hu Friedy, Chicago, IL, USA, equipped with a Brodonic spring device (Dentramar, Waalwijk, Holland).

Furthermore, patients were asked to indicate if one technique was preferable to the other in terms of post-operative course and aesthetics.

In terms of post-operative course, patients were asked to select one of the following choices: bad, bothersome, good, optimum. In the case of differences in post-operative discomfort between the test and control surgical procedures, the patient had to indicate if this was due to the healing of the buccal area or to the palate wound.

In terms of aesthetic outcome, patients were asked to express their opinion about the appearance of the treated teeth by selecting one of the following choices: bad, sufficient, good, optimum aesthetics. In the case of difference in the aesthetic opinion between test and control teeth, patients were asked to indicate the reason(s) for

this difference, selecting one or more of the following choices: difference in tooth length, difference in colour blending, difference in gingival thickness.

#### Surgical technique (Fig. 1)

Both test and control defects were treated with the same design of the covering flap that included:

- two horizontal incisions (extended 3 mm each in the mesial-distal direction) performed at a distance from the vertex of the anatomic papilla equal to the depth of the recession; and
- two bevelled vertical-releasing incisions that extended into the alveolar mucosa.

A split-thickness flap was elevated and all muscle insertions were elimi-

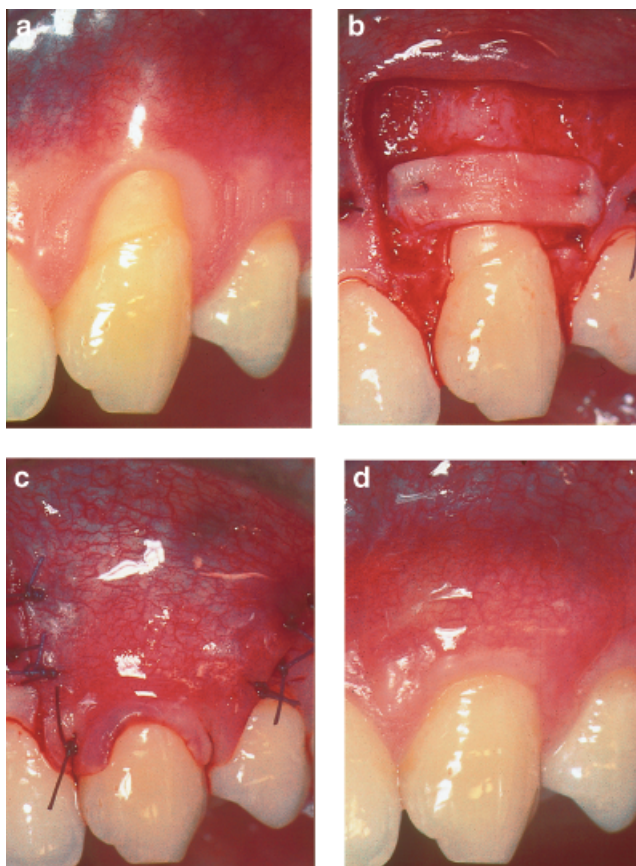


Fig. 1. Surgical technique adopted in the test site. (a) Pre-operative clinical view of the test-treated tooth: 4 mm depth gingival recession with 1 mm height of keratinized tissue is present at tooth #23. (b) The connective tissue graft is sutured apical to the CEJ with double external vertical mattress sutures. The graft covers the bone dehiscence up to the level of the bone crest (see text for further details). (c) Suture of the covering flap (see text for more details). The flap completely covers the connective tissue graft. (d) The post-operative (1-year) clinical view shows the treated tooth with the same soft tissue margin originally present apical to the recession defect, a good colour blending of the treated area and the increase in gingival thickness limited to the area of root exposure.

nated in order to facilitate its coronal displacement. The root surface was mechanically treated with the use of curettes. Only that portion of the root surface with loss of clinical attachment (gingival recession+probing pocket depth) was instrumented. Root planing was terminated when a clean and hard root surface was obtained.

The connective tissue graft was harvested from the palate with the "trap-door" approach described by Harris (1992) when the shape of the palate and the thickness of the palatal soft tissues permitted it. Otherwise, in the presence of unfavourable palatal anatomic conditions, an epithelized graft was taken and it was subsequently disepithelized by means of a blade.

The mesio-distal length of the graft was 6 mm greater than the width of the recession measured at the level of the CEJ.

In the test sites, the apico-coronal dimension of the graft was equal to the depth of the bone dehiscence (measured from the CEJ to the most apical extension of the buccal bone crest) minus the pre-operative height of keratinized tissue apical to the recession defect. The thickness of the graft, measured with an Iwansson gauge<sup>†</sup> (Baldi et al. 1999), was less than 1 mm. The connective tissue graft was positioned apical to the CEJ at a distance equal to the height of keratinized tissue originally present apical to the recession defect (Fig. 1).

A double vertical mattress suture was performed to anchor the connective tissue graft to adjacent buccal soft tissue. This suture was started by perforating the buccal soft tissue mesial/distal to the recession, and was passed below the releasing incision and through the graft, from the internal to the external surface. Then it was brought 1 mm coronally on the external aspect of the graft and passed again through the graft (from the external to the internal aspect) and below the releasing incision perforating (from the internal to the external aspect) the adjacent buccal soft tissue 1 mm coronal to the point where the suture was started; here a surgical knot was performed to complete the suture (Fig. 1).

An identical suture was performed at the other side of the recession defect (distal/mesial) to complete graft stabilization.

This positioning of the graft left the more coronal portion of the root exposure for coverage by the gingival tissue originally present apical to the recession defect, which will then become the gingival margin of the treated tooth (Fig. 1).

In the control tooth, the apico-coronal length of the graft was 3 mm greater than the depth of the bone dehiscence and the thickness of the graft was greater than 1 mm.

The graft was positioned at the level of the CEJ and anchored at the base of the anatomic papillae with two interrupted sutures.

The remaining buccal soft tissue of the anatomic interdental papillae was disepithelized to create connective tissue beds to which the surgical papillae of the covering flap were sutured.

The suture of the covering flap started with two interrupted sutures performed in the most apical extension of the mesial- and distal-releasing incisions, and then it proceeded coronally, with other interrupted sutures, each of them directed, from the flap to the adjacent buccal soft tissue, in the apical-coronal direction. After these sutures, the most marginal portion of the covering flap was stable in its coronal position without disrupting forces acting on it at the time of the final suture. This last suture was a sling suture. It started perforating the distal surgical papilla (from the external to the internal) and the corresponding disepithelized anatomic papilla reaching the palate side, and then it was brought mesially, and buccally passing below the mesial contact point (without perforating the mesial interdental papilla). Then the mesial surgical and anatomical papilla were perforated (from the external to the internal) and, once in the palatal side, the suture was brought distally and buccally passing below the distal contact point, where it was closed with a surgical knot (Fig. 1).

This sling suture was performed to permit a precise adaptation of the buccal flap on the underlying connective tissue graft and to stabilize every single surgical papilla over the interdental connective tissue bed.

#### Post-surgical infection control

Patients were instructed not to brush their teeth in the treated area, but to rinse their mouth with chlorhexidine solution (0.12%) twice daily for 1 min.

Fourteen days after the surgical treatment, the sutures were removed. Plaque control in the surgically treated area was maintained by chlorhexidine rinsings for an additional 2 weeks. After this period, the patients were again instructed in mechanical tooth cleaning of the treated tooth region using a soft toothbrush and a roll technique. All patients were recalled for prophylaxis 1, 3 and 5 weeks after suture removal and, subsequently, once every 3 months until the final examination (12 months).

#### Covering flap dehiscence

The dehiscence of the covering flap (FD), measured from the level of the CEJ to the most coronal extension of the flap covering the graft, was evaluated every 15 days during the first month after surgery and every single month for the remaining experimental period (11 months).

#### Data analysis

Statistical Application Software<sup>‡</sup> was used for the statistical analysis.

- Paired Student's *t*-test was applied to compare test and control groups in terms of REC depth, CAL, PPD, GH values at baseline and the thickness and length of the connective tissue graft harvested from the palate at the time of surgery.
- General linear models were fitted and multiple regression ANOVA for repeated measures with split-plot design was used to evaluate the existence of any significant difference as regards CAL, REC depth, PPD, GH and FD between the two techniques, time (1-year data as compared to data at baseline). In the case of significance, Bonferroni *t*-test was applied as a multiple comparison test.
- General linear models were also fitted relating 1-year % root coverage and 1-year CAL gain to one categorical (technique) and four continuous (GH, PPD, REC depth, REC width) factors as covariates (ANCOVA).
- $\chi^2$  analysis was used to evaluate the differences between techniques with respect to % of complete root coverage and to evaluate the technique preferred by the patient, and the subjective factors responsible for the difference between procedures.

<sup>†</sup>Hu-Friedy, Chicago, IL, USA.

<sup>‡</sup>SAS, version 6.09, SAS Institute, Cary, NC.

– The Wilcoxon signed-rank test was used to evaluate any significant difference between techniques in scores from the questionnaire assessment concerning subjective experiences in terms of post-operative discomfort/pain and final aesthetic outcome.

## Results

Following the initial oral hygiene phase as well as at the post-treatment examinations, all subjects showed low frequencies of plaque harbouring tooth surfaces (FMPS <20%) and bleeding gingival units (FMBS <15%), indicating a good standard of supragingival plaque control during the study period.

### Baseline defect characteristics

Baseline defect characteristics (mean values  $\pm$ SD) are shown in Table 1.

No statistically significant difference was observed among the two matched experimental groups in any of the considered clinical parameters, indicating that the randomization process had been effective.

All patients enrolled in the study indicated tooth length as the cause of the aesthetic problem associated with the recession defect. Two of them also indicated the lack of gingiva, while none mentioned the difference in colour as a significant unaesthetic factor.

In the *test* group, the mean thickness of the graft was  $0.7 \pm 0.38$  mm while the mean height (apical–coronal dimension) was  $4.9 \pm 1.22$  mm. All grafts were harvested by means of the “trap-door approach” and primary intention palate wound healing was accomplished in all treated cases. At the 15-day control visit, no signs of primary palatal flap dehiscence or necrosis were demonstrated.

In the *control* group, the mean thickness of the graft was  $1.4 \pm 0.52$  mm while the mean height was  $9.6 \pm 2.11$  mm. In this group, the “trap-door” approach was used in nine

patients, while in the remaining six an epithelized graft was taken from the palate. Thereafter, complete closure of the palatal wound was accomplished only in nine patients. In three of them, a necrosis of the primary palatal flap occurred during the first healing period (15 days).

### 1-year clinical outcome

**REC depth:** A significant ( $p < 0.01$ ) REC decrease was observed in both the groups (from  $4.0 \pm 0.76$  to  $0.1 \pm 0.31$  mm at test sites and from  $3.9 \pm 0.80$  to  $0.3 \pm 0.62$  mm at controls), with a similar ( $p = \text{NS}$ ) decreasing rate for both groups of teeth. This change in recession depth corresponded to a root coverage of  $97.3 \pm 7.01\%$  and  $94.7 \pm 11.21\%$  in the test and control group, respectively.

Complete root coverage (up to the CEJ) was accomplished in 86.7% (13 out of 15 of the treated cases) in the test group and in 80% (12 out of 15) in the control group ( $\chi^2 = 0.24$ ; NS).

The significance of factors affecting 1-year % root coverage was evaluated by fitting a general linear model (Table 2).

The variables significantly affecting the % root coverage was the REC depth at baseline ( $F = 17.36$ ;  $p < 0.01$ ) and GH at baseline ( $F = 27.49$ ;  $p < 0.01$ ): the % root coverage increased with increasing initial recession depth and increasing gingival height.

No significant effect was found with regard to the type of technique used ( $F = 0.31$ ; NS).

**CAL:** No significant difference between the groups was found at baseline and a significant ( $p < 0.01$ ) CAL decrease (CAL gain) in both groups of teeth was found (from  $5.1 \pm 0.80$  to  $1.1 \pm 0.31$  mm at test sites and from  $5.0 \pm 0.76$  to  $1.9 \pm 0.52$  mm at controls). This change in CAL corresponded to a CAL gain of  $3.9 \pm 0.70$  and  $3.1 \pm 0.74$  in the test and control group, respectively ( $p < 0.01$ ).

Table 2. Results by fitting a general linear model relating 1-year % root coverage to one categorical variable (technique) and four continuous (GH, PPD, REC depth and REC width) factors as covariates (ANCOVA)

Source	F-ratio	p-Value
GH basal	27.49	<.01
PPD basal	0.78	NS
REC depth basal	17.36	<.01
REC width basal	2.64	NS
Technique	0.31	NS

Analogous results were found with respect to PPD and GH. In particular, PPD remained shallow in both groups although a significantly greater increase ( $p < 0.01$ ) was demonstrated in the control than the test group. Similarly, the average increase in GH was statistically significant for both groups, but greater in the control group.

Changes in clinical parameters at 1 year are summarized in Table 3.

**Flap dehiscence:** Statistical analysis showed a significant relationship between techniques ( $F = 79.7$ ;  $p < 0.01$ ); in particular, in control sites, covering flap dehiscence occurred in eight out of 15 control sites and, in six of them, was already clinically present at the 15-day visit (at the time of suture removal). As shown in Fig. 2, the amount of flap dehiscence increased during the following 15 and 30 days, after which it remained stable for the entire duration of the study. In the eight teeth that experienced dehiscence of the covering flap, root exposure occurred only in three cases, while in five teeth the exposed graft remained at the level of the CEJ covering the gingival recession.

On the other hand, in the test sites, covering flap dehiscence occurred in only two teeth, and in both cases it was associated with root exposure. Graft exposure was never demonstrated.

**Post-operative course:** Patients reported a significantly (Wilcoxon signed-rank test;  $p < 0.01$ ) better post-operative course in the test group (average score  $3.1 \pm 0.35$  with an average rank of 19.1), with respect to the control group (average score  $2.6 \pm 0.51$  with an average rank of 11.9). Seven patients indicated a greater discomfort in the control sites as compared with the test sites, while the remaining eight did not report any difference between sites ( $\chi^2 = 14.0$ ;  $p < 0.01$ ). All seven patients indicating a greater discomfort in the control sites referred a more painful

Table 1. Clinical parameters at baseline (MV  $\pm$ SD) (significance was obtained from paired Student's *t*-test)

	Test group	Control group	<i>t</i>	<i>p</i>
REC depth	$4.0 \pm 0.76$	$3.9 \pm 0.80$	0.25	NS
CAL	$5.1 \pm 0.80$	$5.0 \pm 0.76$	0.29	NS
PPD	$1.1 \pm 0.26$	$1.1 \pm 0.35$	0.56	NS
GH	$1.1 \pm 0.26$	$1.2 \pm 0.41$	1.46	NS

Table 3. Clinical change at 1 year (MV ±SD) (significance was obtained from paired Student's *t*-test)

	Test group	Control group	<i>t</i>	<i>p</i>
Root coverage	3.9 ± 0.71	3.6 ± 0.72	1.73	NS
CAL gain	3.9 ± 0.70	3.1 ± 0.74	4.58	<.01
PPD increase	0.1 ± 0.25	0.5 ± 0.51	3.23	<.01
GH increase	2.3 ± 0.59	3.3 ± 0.72	5.17	<.01

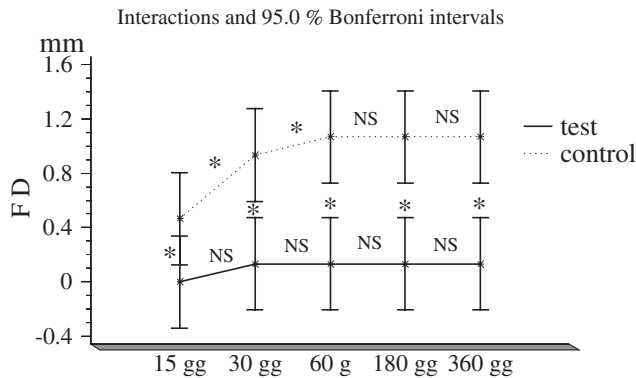


Fig. 2. Time-related variations in FD in both test and control groups; \**p* < 0.01.

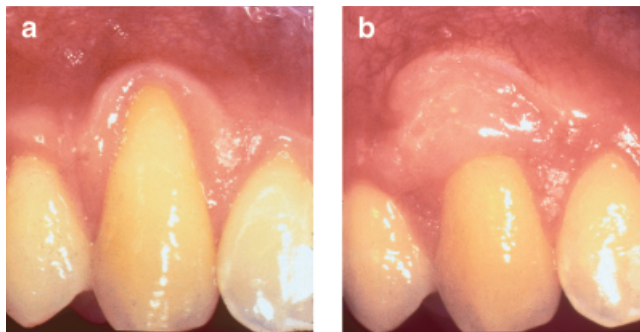


Fig. 3. Pre- (a) and post- (b) operative clinical images of the contralateral control-treated tooth. Complete root coverage has been achieved. The 1-year clinical view shows the unaesthetic white-scar appearance of the grafted area due to dehiscence of the covering flap. It can be speculated that the size and thickness of the graft and its excessive coronal placement might have reduced the vascular exchange between the covering flap and the underlying receiving connective tissue bed, causing the complete recession of the flap. Furthermore, the increase in gingival thickness extends beyond the area of root exposure.

palate wound healing as the cause ( $\chi^2 = 12.0$ ; *p* < 0.01).

**Aesthetic outcome:** Patients were more satisfied (Wilcoxon signed-rank test; *p* < 0.01) with the appearance of the test-treated areas (average score 3.5 ± 0.51 with an average rank of 21.1) with respect to the control sites (average score 2.5 ± 0.63 with an average rank of 9.9). In particular, in the test group, eight subjects out of 15 reported an optimum aesthetic result and the remaining seven a good result, while, in the control group, eight subjects reported a good aesthetic outcome, six were not completely satisfied and one

indicated an absolutely unsatisfactory aesthetic result. When asked about the preferred procedure, 12 patients reported better aesthetics of the test-compared with control-treated sites ( $\chi^2 = 24.0$ ; *p* < 0.01). Nine of them indicated the excessive thickness of the control-treated areas as one of the reasons for the worst result (in four patients the excessive thickness was the only negative factor). The poor colour blending was indicated by eight patients, while only one patient indicated excessive tooth length as one of the reasons (together with the excessive thickness and poor colour blending)

for the worst aesthetic results in the control sites.

**Discussion**

The goal of the present study was to compare two surgical approaches of the bilaminar procedure in terms of (1) root coverage outcomes and (2) aesthetic appearance of the surgically treated sites.

In order to have a precise method of evaluating the differences between the two techniques, considerable effort was taken to identify test and control sites as similarly as possible in the upper jaw of the same mouth. The selection of the gingival lesion was therefore very strict and justifies the relatively small number of patients included in the study.

Present data indicate that the two surgical approaches adopted in the study were highly effective and predictable in obtaining root coverage of gingival recessions. In fact, both techniques resulted in a very high percentage of root coverage (97.3% in the test group and 94.7% in the control group) and complete soft tissue root coverage (up to the CEJ) was accomplished in the great majority of test- (86.7%) and control-treated (80%) cases. No clinical and statistical differences were demonstrated in root coverage outcomes between the two surgical approaches adopted in the present study. This rate of successful outcomes of the treatment is similar or even somewhat higher than that previously reported in the literature for the bilaminar techniques (Harris 1992, Allen 1994, Wennstrom & Zucchelli 1996) and for other root coverage procedures (Wennstrom 1994).

The regression model, adopted in the present study, indicated that the % of root coverage was positively affected by initial recession depth and gingival height. These data indicate that better root coverage outcome can be achieved in recession defect with deeper root exposure and with higher gingival tissue apical to the defect. The efficacy of bilaminar techniques in the treatment of deep recession has already been demonstrated in the literature (Zucchelli et al. 1998), while it can be speculated that the presence of high gingival tissue apical to the defect may have facilitated covering flap management and suturing technique, while maximizing the possibility to achieve and maintain complete coverage of the underlying connective

tissue graft. This may have contributed to reducing the risk of flap dehiscence and thus participated in improving the root coverage outcome of the bilaminar technique.

Both techniques, adopted in the present study, resulted in a clinically and statistically highly significant clinical attachment gain (statistically greater in the test-treated teeth) with no significant changes in the depth of the probing buccal pocket depth. Furthermore, a clinically significant increase in the width of keratinized tissue was demonstrated after both the adopted surgical procedures. This increase was statistically greater in the control-treated teeth.

Data resulting from the questionnaire of the present study indicated that: (i) patients with aesthetic demands usually complain about the excessive length of the tooth with gingival recession; (ii) once root coverage has been achieved, other factors like gingival thickness and colour blending become important in patient evaluation of the aesthetic outcome of a root coverage surgical procedure; and (iii) the type (primary or secondary) of palatal wound healing greatly influences the patient's post-operative course.

The reduced thickness and apical-coronal dimension of the graft, together with its positioning apical to the CEJ, were the most significant differences between the two surgical techniques adopted in the present study. These modifications were primarily made to improve the aesthetic outcome of the bilaminar procedure. The reduced thickness and height of the graft allowed one to minimize the obstacle hindering the blood supply from the receiving connective tissue bed to the covering flap. During the first healing phase, in fact, the connective tissue graft represents an obstacle to the nutritional exchanges between the periosteal beds lateral and apical to the bone dehiscence and the coronally advanced covering flap. The bigger and thicker the graft, the greater the obstacle and the greater the risk of covering flap dehiscence and consequently graft exposure. This is confirmed by the present data, which indicated a high percentage (53%) of flap dehiscence in the control group, while no graft exposure was observed in the test-treated teeth. When the connective tissue graft is exposed, it rapidly becomes covered by a keratinized epithelium and its colour becomes

similar to that of the patient's palate. The consequence of this is a poor colour blending of the treated area with respect to the adjacent soft tissues. The importance of gingival colour in terms of post-operative aesthetics was demonstrated in the present study by the fact that covering the root exposure with gingival tissues of different colours from that of adjacent soft tissues did not satisfy the patient's aesthetic demands. In the present patient population, six patients were not satisfied with the aesthetic appearance of the control-treated sites, despite the complete root coverage that had been achieved and this was due to poor colour blending of the surgically treated area. In order to satisfy the patient's request fully, recession defects should be completely (up to the CEJ) covered with gingival tissues, the colour and thickness of which should not be distinguishable from those of adjacent soft tissues. The reduced dimensions of the graft may improve the aesthetic outcome also by minimizing the increase in gingival thickness at the surgically treated site. When the connective tissue graft is extended beyond the buccal bone crest, as was performed in the control group of the present study, it may cause an excessive soft tissue thickness in close proximity to the fornix (especially in a patient with a small vestibulum). This increased thickness may not only alter the aesthetic harmony of mucogingival tissues but may also be the cause of food accumulation that can prove to be very unpleasant for the patient. The negative impact of the excessive soft tissue thickness on the patient's evaluation of the aesthetic appearance of the surgically treated area has been demonstrated in the present study: 10 patients complained about the excessive thickness of the control sites and to which they attributed one of the reasons for the worst aesthetic outcome of the control compared to test-treated teeth.

The increase in the soft tissue thickness consequent to the use of a connective tissue graft should be limited to the area previously occupied by the root exposure. Therefore, the thickness of the connective tissue graft should be changed according to the presence and the amount of root structure loss (caries, abrasions) associated with the gingival recession. In the presence of deep abrasion, a thicker graft should be used to compensate the loss of hard tissue

and to provide the treated tooth with a correct emergence profile.

The positioning of the graft apical to the CEJ further contributed to improving the aesthetic outcome after the bilaminar procedure. Firstly, it allowed the most coronal portion of the root (close to the CEJ) available for the gingival tissue originally present apical to the recession defect. Therefore, the chromatic characteristics and the thickness of the gingival margin, originally present apical to the root exposure, that will become the marginal tissue of the treated tooth, are not modified and thus result in being indistinguishable from those of adjacent teeth. Secondly, the apical positioning of the graft allowed for the increase of the vascular area lateral to the root exposure, thus reducing the risk of covering flap dehiscence and unaesthetic graft exposure.

The use of thin suture (6-0) together with the utilization of a graft-suturing technique that displaced the surgical knot out of the surgical area and minimized the amount of suture interposed between the graft and the covering flap, may have contributed to reducing the risk of flap dehiscence and thus participated in improving the aesthetic outcome of the bilaminar procedure.

The surgical approach utilized in the test sites of the present study caused less post-operative discomfort/pain than the more traditional bilaminar technique adopted in the control sites. Seven patients, in fact, reported greater discomfort in the control sites and this was due to the palate wound. A possible explanation for this difference was that, in all test sites, the reduced apico-coronal dimension and minimal thickness of the graft permitted the use of the "trap-door approach" to harvest the connective tissue grafts, and thus allowed for a primary intention palatal wound healing that was less traumatic for the patients. Conversely, in six of the control cases the greater height and thickness of the graft obliged the clinician to take an epithelized graft from the palate and this caused a more painful secondary intention palatal wound healing.

## Conclusions

The results of the present study demonstrated that the proposed approach of the bilaminar technique was a very effective procedure for the treatment

of isolated gingival recessions in patients with aesthetic demands since it resulted in complete soft tissue root coverage in the great majority of treated cases. No significant differences were demonstrated in terms of root coverage between the two procedures adopted in the study. Conversely, better results in terms of aesthetic outcome and post-operative course were indicated by the patients in sites treated with the novel approach compared to sites treated with a more conventional bilaminar technique.

The reduced thickness and apico-coronal dimension of the connective tissue graft, together with its positioning apical to the CEJ, facilitated the graft coverage by the coronally advanced flap and improved the aesthetic outcome. In fact, if the covering flap remained stable in the coronal position it was able to hide the unaesthetic white-scar appearance of the graft and to provide the treated tooth with the same gingival margin originally present apical to the recession defect. The proposed surgical approach permitted the association of the aesthetic advantages of the coronally advanced flap to the increase in soft tissue thickness and gingival height consequent to the use of free graft surgical techniques.

## Zusammenfassung

*Zweischichtige Techniken für die Behandlung von Rezessionsdefekten. Eine vergleichende klinische Studie*

**Hintergrund:** Die vollständige Deckung der Wurzeloberfläche ist das primäre Ziel, das bei der Therapie von fazialen Rezessionen bei Patienten mit ästhetischen Ansprüchen erreicht werden soll. Weiterhin sollte die Rezessionsdeckung, wenn sie den Ansprüchen des Patienten vollends entsprechen soll, mit einer Dicke und Farbe der Gingiva erreicht werden, die nicht vom benachbarten Gewebe zu unterscheiden sind.

**Zielsetzung:** Vergleich der Therapieergebnisse von 2 chirurgischen Varianten der zweischichtigen Technik im Halbseitenversuch hinsichtlich (1) Rezessionsdeckung und (2) ästhetischer Erscheinung der chirurgisch behandelten Stellen.

**Material und Methoden:** 15 junge und parodontal gesunde Personen mit jeweils 2 Rezessionsdefekten ähnlicher Größe an kontralateralen Zähnen im ästhetischen Bereich des Oberkiefers wurden in die Studie aufgenommen. Alle Rezessionen gehörten in die Miller-Klassen I oder II. Die Randomisierung für die Test- und Kontrollbehandlung erfolgte unmittelbar präoperativ durch Münzwurf. Alle Defekte wurden nach einer zweischichtigen chirurgischen Technik behandelt: Die Unterschiede zwischen Test- und Kontrollstellen

bestanden in Größe, Dicke und Positionierung des Bindegewebstransplantates. Die klinische Nachuntersuchung erfolgte 1 Jahr postoperativ.

**Ergebnisse:** Beide zweischichtigen Techniken führten zu einem hohen Prozentsatz von Wurzeldeckung (Test: 97,3%; Kontrolle: 94,7%) und kompletter Wurzeldeckung (Gingivarand an der Schmelz-Zement-Grenze [SZG]) (Test: 86,7%; Kontrolle: 80%) ohne statistisch signifikante Unterschiede zwischen beiden Gruppen. Allerdings wurden mit der Testtherapie bessere ästhetische Ergebnisse erzielt als mit der Kontrollbehandlung.

**Schlussfolgerung:** Die vorgestellte Modifikation der zweischichtigen Technik verbesserte die ästhetischen Ergebnisse. Die reduzierte Größe und minimale Dicke des Bindegewebstransplantates zusammen mit seiner Positionierung apikal der SZG erleichterten eine Deckung mittels eines koronalen Verschiebepappens.

## Résumé

*Techniques bilaminaires pour le traitement des récessions. Une étude clinique comparative.*

**Objectif:** Un recouvrement complet de la racine est le premier objectif lorsque l'on traite des récessions gingivales chez les patients ayant une demande esthétique. De plus, afin de satisfaire totalement la demande du patient, cette couverture radicaire doit aussi être réalisé par des tissus mous de couleur et d'épaisseur qui ne se distinguent pas des tissus mous adjacents. Le but de cette étude en bouche séparée était de comparer le devenir de deux approches chirurgicales de la technique bilaminare pour (i) le recouvrement de la racine et (ii) l'apparence esthétique des sites traités chirurgicalement.

**Matériel et Méthodes:** 15 sujets jeunes et indemnes de maladie parodontale et systémique présentant deux récessions de profondeur similaires sur des dents contralatérales dans des zones esthétiques du maxillaire furent enrôlés dans cette étude. Toutes les récessions étaient des classes I ou II de Miller. La répartition pour les traitements test ou contrôle fut tirée à pile ou face juste avant la chirurgie. Toutes les lésions furent traitées par la technique bilaminare, la différence entre les groupes résidant dans la taille, l'épaisseur et le positionnement du greffon de tissus conjonctif. La réévaluation clinique fut faite un an après la chirurgie.

**Résultats:** Les deux techniques bilaminaires ont entraîné un fort pourcentage de recouvrement radicaire (97,3% pour le groupe test et 94,7% pour le groupe contrôle) et le recouvrement complet (gingive marginale au niveau de la CEJ) (86,7% dans le groupe test et 80% pour le groupe contrôle) sans différence statistiquement significative entre elles. Par contre, un meilleur rendu esthétique et suites post opératoires furent rapportés par les patients pour le traitement test.

**Conclusions:** La modification proposée de cette technique bilaminare améliore le devenir esthétique. La taille réduite et l'épaisseur minimale greffon conjonctif et son positionnement

apical au CEJ, ont facilité le recouvrement du greffon par le lambeau déplacé coronairement.

## References

- Allen, A. L. (1994) Use of the suprapariosteal envelope in soft tissue grafting for root coverage. II. Clinical results. *International Journal of Periodontics and Restorative Dentistry* **14**, 303–315.
- Allen, E. P. & Miller, P. D. (1989) Coronal positioning of existing gingiva: short-term results in the treatment of shallow marginal tissue recession. *Journal of Periodontology* **60**, 316–319.
- Baldi, C., Pini-Prato, G., Magliaro, U., Nieri, M., Saletta, D., Muzzi, L. & Cortellini, P. (1999) Coronally advanced flap procedure for root coverage. Is flap thickness a relevant predictor to achieve root coverage? A 19 case series. *Journal of Periodontology* **70**, 1077–1084.
- Borghetti, A. & Gardella, J. P. (1990) Thick gingival autograft for the coverage of gingival recession: a clinical evaluation. *International Journal of Periodontics and Restorative Dentistry* **10**, 217–229.
- Bouchard, P., Etienne, D., Ouhayoun, J. & Nilveus, R. (1994) Subepithelial connective tissue grafts in the treatment of gingival recessions. A comparative study of 2 procedures. *Journal of Periodontology* **65**, 929–936.
- Bruno, J. F. (1994) Connective tissue graft technique assuring wide root coverage. *International Journal of Periodontics and Restorative Dentistry* **14**, 127–137.
- Caffesse, R. G., Kon, S., Castelli, W. A. & Nasjleti, C. E. (1984) Revascularization following the lateral sliding flap procedure. *Journal of Periodontology* **55**, 352–359.
- Grupe, H. J. & Warren, R. (1956) Repair of gingival defects by a sliding flap operation. *Journal of Periodontology* **27**, 92–99.
- Guinard, E. A. & Caffesse, R. G. (1978) Treatment of localized gingival recessions. III. Comparison on results obtained with lateral sliding and coronally repositioned flaps. *Journal of Periodontology* **49**, 457–461.
- Harris, R. (1992) The connective tissue and partial thickness double pedicle graft: a predictable method of obtaining root coverage. *Journal of Periodontology* **63**, 477–486.
- Holbrook, T. & Ochsenbein, C. (1983) Coverage of denuded root surface with a one-stage gingival graft. *International Journal of Periodontics and Restorative Dentistry* **3**, 9–27.
- Langer, B. & Langer, L. (1985) Subepithelial connective tissue graft technique for root coverage. *Journal of Periodontology* **56**, 715–720.
- Matter, J. (1980) Free gingival graft for the treatment of gingival recession. A review of some techniques. *Journal of Clinical Periodontology* **9**, 103–117.
- Miller, P. D. (1985) Root coverage using a free soft tissue autograft following citric acid application. III. A successful and predictable procedure in areas of deep-wide recession.



- International Journal of Periodontics and Restorative Dentistry* **5**, 15–37.
- Mlinek, A., Smuckler, H. & Buchner A. (1973) The use of free gingival grafts for the coverage of denuded roots. *Journal of Periodontology* **44**, 248–254.
- Nelson, S. W. (1987) The subpedicle connective tissue graft. A bilaminar reconstructive procedure for the coverage of denuded root surfaces. *Journal of Periodontology* **58**, 95–102.
- O’Leary, T.J., Drake, R. B. & Naylor, J. E. (1972) The plaque control record. *Journal of Periodontology* **43**, 38.
- Raetzke, P. B. (1985) Covering localized areas of root exposure employing the “envelope” technique. *Journal of Periodontology* **56**, 397–401.
- Sullivan, H. C. & Atkins, J. H. (1968) Free autogenous gingival grafts. III. Utilization of grafts in the treatment of gingival recession. *Periodontics* **6**, 152–160.
- Tenenbaum, H., Klewansky, P. & Roth, J. J. (1980) Clinical evaluation of gingival recession treated by coronally repositioned flap technique. *Journal of Periodontology* **51**, 686–690.
- Tolmie, P. N., Rubins, R. P., Buck, G. S., Vagianos, V. & Lanz, J. C. (1991) The predictability of root coverage by way of free gingival autografts and citric acid application: an evaluation by multiple clinicians. *International Journal of Periodontics and Restorative Dentistry* **11**, 261–271.
- Wennstrom, J. L. (1994) Proceedings of the 1st European workshop on periodontology. In: *Mucogingival surgery*, eds. Lang, N. P. & Karring, T., pp. 193–209. Berlin: Quintessence Publishing Co.
- Wennstrom, J. L. & Zucchelli, G. (1996) Increased gingival dimensions. A significant factor for successful outcome of root coverage procedures? A 2-year prospective clinical study. *Journal of Clinical Periodontology* **23**, 770–777.
- Zucchelli, G., Clauser, C., De Sanctis, M. & Calandriello, M. (1998) Mucogingival versus GTR procedures in the treatment of deep recession type defects. *Journal of Periodontology* **69**, 139–145.
- Zucchelli, G. & De Sanctis, M. (2000) Treatment of multiple recession type defects in patients with aesthetic demands. *Journal of Periodontology* **71**, 1506–1514.

Address:  
 G Zucchelli  
 Department of Periodontology  
 Bologna University  
 Via S. Vitale 59 40125  
 Bologna  
 Italy  
 Tel: +39 051 278011  
 Fax: +39 051 275208  
 E-mail: giovanni.zucchelli@unibo.it